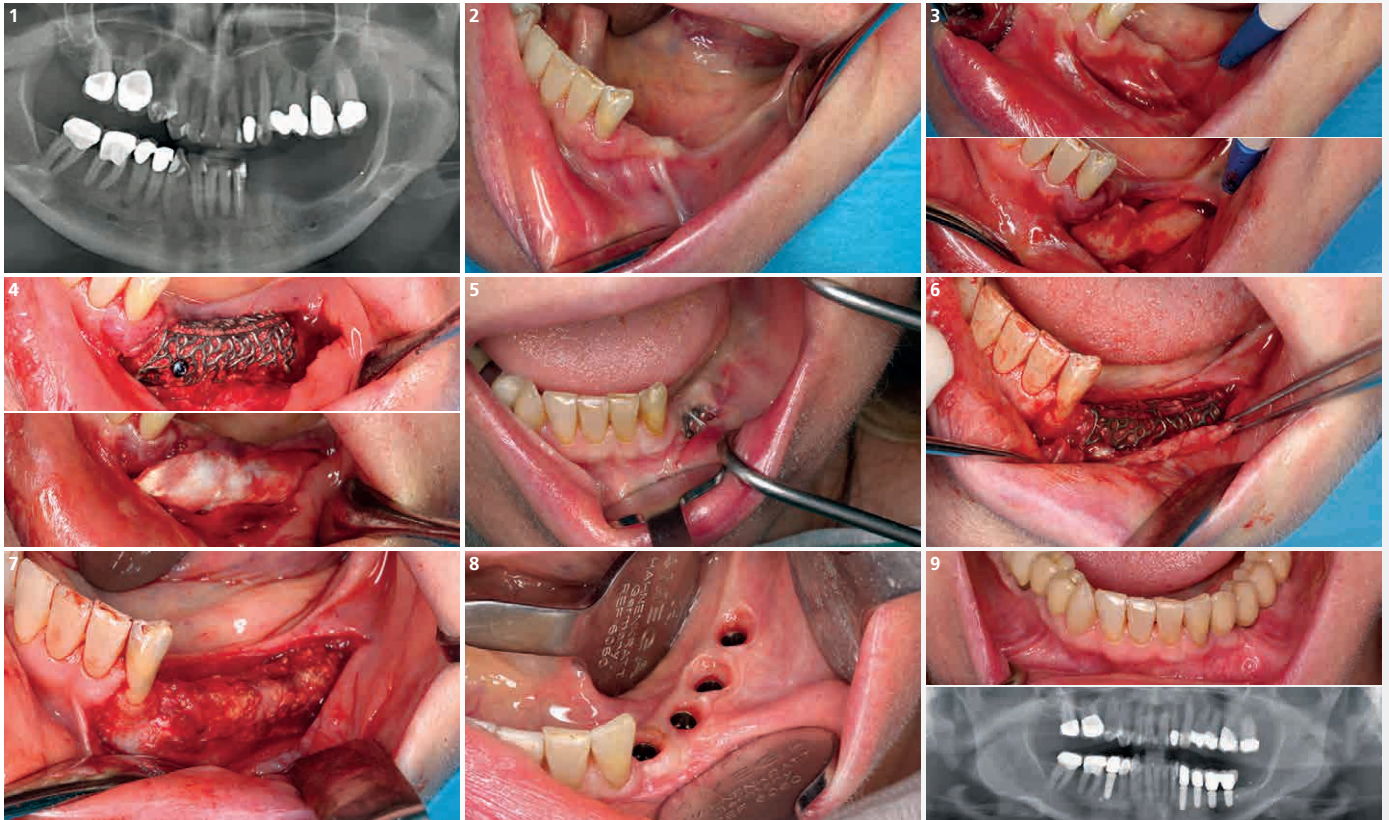


# Vertical Defect in the posterior mandible

Dr. Sarah Krause



1 Radiographic image showing the vertical bone deficit in left mandible

2 Clinical situation before opening the area.

3 The poncho flap design is applied starting in the retromolar area until the distal region of teeth 32

4 Cortical bone is removed with trephine, crushed and mixed with Geistlich Bio-Oss® (50:50), followed by a collagen membrane application (Geistlich Bio-Gide®)

5 Dehiscence after 1,5 month. The soft tissue was de-epithelialized and a free gingival graft was sutured to protect the exposition.

6 After 6 months, the ridge incision is applied to access the 3D titanium scaffold

7 Buccal view of the regenerated bone. Even after soft tissue management, the bone was regenerated

8 Four implants are placed and the soft tissue is healed showing the contour provided by the good adaptation of the provisional prosthesis

9 Clinical and radiographic situation after the final prosthesis and the soft tissue frenum removal.